

Interactive CardioVascular and Thoracic Surgery

Translumbar treatment of type II endoleaks after endovascular repair of abdominal aortic aneurysm

Michael Gorlitzer, Gerard Mertikian, Hubert Trnka, Alexander Froeschl, Johann
Meinhart, Gabriel Weiss, Martin Grabenwoeger and Thomas Rand
Interact CardioVasc Thorac Surg 2008;7:781-784; originally published online Jul 2,
2008;
DOI: 10.1510/icvts.2008.178624

The online version of this article, along with updated information and services, is
located on the World Wide Web at:
<http://icvts.ctsnetjournals.org/cgi/content/full/7/5/781>

Interactive Cardiovascular and Thoracic Surgery is the official journal of the European Association
for Cardio-thoracic Surgery (EACTS) and the European Society for Cardiovascular Surgery
(ESCVS). Copyright © 2008 by European Association for Cardio-thoracic Surgery. Print ISSN:
1569-9293.

Institutional report - Aortic and aneurysmal Translumbar treatment of type II endoleaks after endovascular repair of abdominal aortic aneurysm

Michael Gorlitzer^{a,*}, Gerard Mertikian^b, Hubert Trnka^b, Alexander Froeschl^a, Johann Meinhart^c,
Gabriel Weiss^a, Martin Grabenwoeger^a, Thomas Rand^b

^aDepartment of Cardiovascular Surgery, Hospital Hietzing, Wolkersbergenstr. 1, A-1130 Vienna, Austria

^bDepartment of Radiology, Hospital Hietzing, Vienna, Austria

^cKarl Landsteiner Institute for Cardiovascular Research, Hospital Hietzing, Vienna, Austria

Received 2 March 2008; received in revised form 5 June 2008; accepted 6 June 2008

Abstract

The modality of treatment and the appropriate time point to treat type II endoleaks after endovascular repair of abdominal aortic aneurysms (EVAR) remain controversial issues. The purpose of the present study was to assess the efficacy of translumbar embolization of type II endoleaks after endovascular repair of aortic aneurysm repair. Eighty-four consecutive patients after EVAR were analyzed for the onset of type II endoleaks. Of these, five patients had experienced translumbar embolization after ineffective intraarterial approach to exclude the endoleak. A combination of several liquid embolic agents was used as sealant. Post-procedural contrast-enhanced ultrasound (CEUS) was used to document the outcome of the embolization. Translumbar embolization was successful in four patients. Complete sealing of the nidus was seen on CEUS 24 h after the procedure. In one patient with a duplication of the inferior vena cava, the procedure was aborted because an additional type Ib endoleak was found. The procedure was well tolerated by all patients. The translumbar approach to treat growing aneurysm sacs in patients with persistent type II endoleaks is safe and well tolerated. The immediate post-interventional outcome as documented on CEUS is promising. Long-term follow-ups are yet to be performed.

© 2008 Published by European Association for Cardio-Thoracic Surgery. All rights reserved.

Keywords: Endovascular; Aortic aneurysm; Endoleak; Embolization

1. Introduction

Endovascular repair of abdominal aortic aneurysms (EVAR) is being performed increasingly more often and has yielded favorable results. The use of EVAR has increased awareness of late failures, including the development of endoleaks, graft migration, continued aneurysm growth and even rupture [1–3].

In patients with type II endoleaks, blood flow through vessels from the aorta or the iliac arteries has to be eliminated in order to protect the aneurysm from systemic pressure. Type II endoleaks occur at a rate of 5–25% [4] after endovascular repair of abdominal aortic aneurysms (AAA). The mode and time point of treating endoleaks remains controversial [5]. At our institution, endoleaks are treated only when the aneurysm sac has grown by 5 mm or more after a follow-up period of six months. If the transarterial approach failed, the translumbar embolization was applied.

Translumbar embolization of type II endoleaks after EVAR proved to be effective [6]. The challenge of this technique lies in correct placement of the needle, utilizing either fluoroscopy or computed tomography as the guiding modality [7].

The purpose of our investigation was to evaluate the efficacy of translumbar embolization of type II endoleaks after endovascular repair of aortic aneurysm repair.

2. Materials and methods

Eighty-four patients who had undergone EVAR between 2001 and 2007 were included in the analysis. Bifurcated devices were used in all cases. The devices used were Talent™ (Medtronic Inc., Santa Rosa, CA; $n=49$), Excluder™ (W.L. Gore & Associates Inc., Flagstaff, AZ; $n=8$) and Zenith™ AAA stentgraft (Cook Medical Inc., Bloomington, IN; $n=27$).

Follow-up information was obtained from clinical data and spiral computed tomographies performed at minimum intervals of 1 week, 6, 12 months, and at yearly intervals thereafter. Transfemoral arteriography was performed to examine hypogastric and superior mesenteric arteries, and assess the involvement of lumbar and inferior mesenteric arteries as a potential cause of type II endoleaks. Furthermore, possible attachment site leaks (type I) or leaks from the endograft itself (type III) were ruled out.

Endoleaks type II were observed in 17 patients (20.2%), endoleaks type I in four patients (4.7%). The type I endoleak was treated by additional stentgrafting in three patients. In one patient a conventional bifurcated prosthesis had to

*Corresponding author. Tel.: +43-1-80110; fax: +43-1-80110-2729.

E-mail address: michael.gorlitzer@wienkav.at (M. Gorlitzer).

be implanted. There was no type III endoleak observed in this cohort. In one patient a rupture occurred due to a penetrating duodenal ulcer.

We report five patients who underwent treatment for type II endoleaks by the translumbar approach. In one patient the source of type II endoleak could not be detected by conventional angiogram, computed tomography or ultrasound. A type Ib was interpreted as a type II endoleak that became apparent after translumbar puncture.

A left-sided translumbar approach under fluoroscopic guidance was used in four patients, and a right-sided CT-guided approach in one patient who had a duplication of the inferior vena cava (IVC) (Fig. 1). The following landmarks were used for the access route: the metallic struts and radiopaque markers of the endograft, strut free zones and vertebral bodies. Actual planning is performed using transversal and coaxial CT images, whereby the distance from the midline to the puncture site as well as the distance and angle from the paravertebral puncture site to the aneurysm sac were determined (Fig. 2).

Once an access site and route through the retroperitoneum had been established, the aneurysm sac was punctured using a 20-gauge needle. 5-French guidance and 3-French micro-catheters were then introduced coaxially to negotiate the nidus. A combination of liquid embolic agents was used as sealants: Onyx[®] liquid embolic system (ev3 Inc., Bonn, Germany) is a premixed, radiopaque injectable agent that solidifies through the process of precipitation. Precipitation is initiated when it comes into contact with aqueous solution, e.g. blood, and the solvent DMSO rapidly diffuses out of the polymer mass. It was used alone or together with synthetic cyan acrylic surgical glue (Glubran[®], GEM S.r.l., Viareggio, Italy) or with fibrin glue (Tissucol[®], Baxter GmbH, Vienna, Austria). Embolization was performed in real time under fluoroscopy, and the embolic agent was set as close as possible to the endoleak. Growth of the aneurysm sac had been identified on CT in all patients.

Additionally, contrast-enhanced ultrasound (CEUS) using microbubbles filled with sulfur hexafluoride (Sonovue[®], Bracco Diagnostics Inc., Milan, Italy) was performed prior

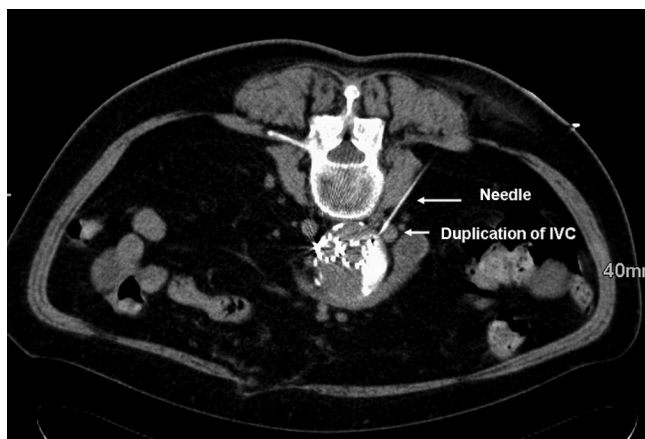


Fig. 1. Needle placement using a right-sided CT-guided approach through the retroperitoneum into the aneurysm sac.

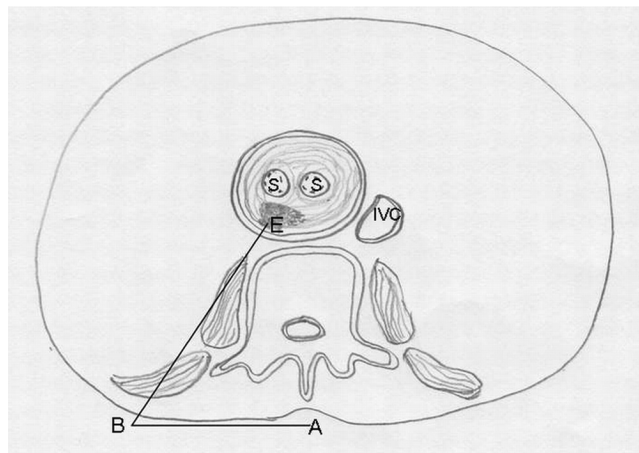


Fig. 2. Evaluation of the access route from the midline (A) to the puncture site (B) and the distance and angle from the paravertebral puncture site to the aneurysm sac (E). S, bifurcated stentgraft; IVC, inferior vena cava.

to the intervention. Post-procedural CEUS was used to document the outcome of the embolization.

3. Results

Seventeen of 84 patients had a type II endoleak after EVAR. Enlargement of the aneurysm sac was seen in five patients.

Three patients had undergone ineffective intra-arterial embolization in the past, followed by growth of the aortic aneurysm sac. One of these patients, in whom the source of the endoleak could not be demonstrated by angiography, was treated by the translumbar approach (Fig. 3). Endoleak in one patient were sealed with the Onyx[®] liquid embolic system in combination with Glubran[®], one with Onyx[®] alone and two with fibrin glue and Glubran[®]. One patient could not tolerate the intra-arterial embolization and was treated by the translumbar approach at a later date. Translumbar embolization was successful in four patients. It achieved complete sealing of the nidus, as demonstrated on CEUS 24 h after the procedure (Fig. 4). In one patient with duplication of the IVC, the procedure was aborted because contrast injection of the nidus demonstrated an additional type Ib endoleak in the contralateral limb of the endograft, for which limb extension was required. The procedure was well tolerated by all patients. No complications related to sac puncture were encountered.

4. Discussion

The management of type II endoleaks remains a highly debated issue in endovascular treatment of abdominal aortic aneurysms because of diverse personal experience and beliefs concerning the long-term outcome of the various approaches. The dilemma as to whether the conservative treatment or intervention is the best approach to the management of type II endoleaks arises from the absence of explicit guidelines on the subject. A type II endoleak that has not sealed within six months after EVAR is termed a persistent endoleak. It is unlikely to seal spontaneously after 12 months [8] and therefore requires close surveillance. Sac enlargement and rupture have been reported in

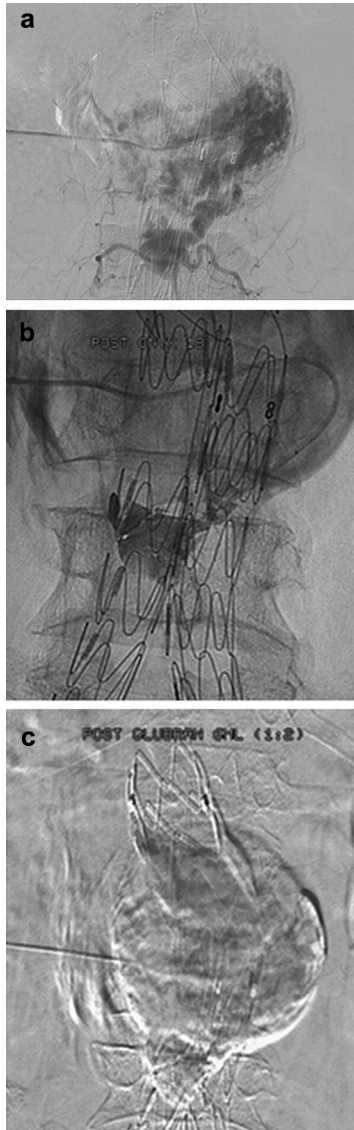


Fig. 3. (a) Identification of a type II endoleak. (b) Translumbar sealing of the type II endoleak with Onyx® and, (c) sealing with Glubran®.

this context [9]. In a recent study performed by Jones et al. [10], persistent endoleaks were associated with several adverse effects. They are at a higher risk of aneurysm sac growth and are thus subject to more frequent interventions. Multivariate analysis showed persistent type II endoleaks to be a significant predictor of aneurysm rupture. In accordance with the strategy used at our institution, patients with a persistent type II endoleak monitored for longer than six months should be considered for more frequent controls of at least three months and a more aggressive approach in terms of re-intervention.

Several authors have confirmed the usefulness of duplex ultrasound for the identification and characterization of endoleaks; it also permits assessment of the direction and velocity of flow [11]. In contrast to computed tomographic angiography (CTA) duplex ultrasound involves no radiation exposure and can be performed and interpreted at a low cost. Additionally, CTA is a less reliable method to establish

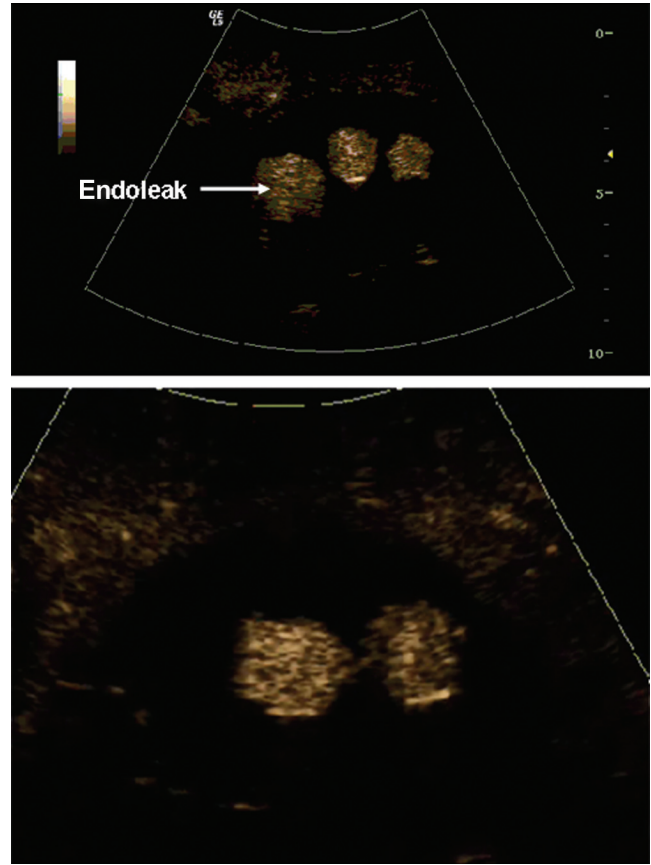


Fig. 4. Complete sealing of the nidus visualized by contrast-enhanced ultrasound.

the origin of type II endoleaks: its sensitivity is only 81% and its specificity, 60% [12]. Contrast-enhanced ultrasound (CEUS) permits correct identification of all types of endoleaks in real time. Besides, it frequently helps to detect collateral vessels causing type II endoleaks [13]. CEUS is a non-invasive, well tolerated, fast, reproducible and highly sensitive imaging modality. All of our patients underwent periodic long-term endograft surveillance with CEUS to identify new endoleaks and monitor existing ones. No side effects related to the ultrasound contrast agent were encountered. However, the limitations of CEUS are worthy of mention: it is operator dependent and, due to the fabric texture of the excluder prosthesis, provides no sufficient signal to identify endoleaks.

Obliteration of the origin of the aortic branches appears to be the key to sustained endoleak repair. These feeding vessels cannot be successfully treated unless the central nidus is eliminated [14]. Translumbar embolization occludes the endoleak itself. It prevents communication between different aortic branch vessels and the aneurysm sac, analogous to central nidus embolization in arteriovenous malformations. As type II endoleaks are dynamic structures resembling an arteriovenous malformation fed by multiple draining vessels, the identification of all collateral vessels may not be mandatory for the translumbar approach. Sustained success is provided by this technique, in contrast to the transarterial approach.

Direct translumbar embolization in prone position dispenses with the need to traverse cavities or organs. This approach is performed under fluoroscopic or CT guidance, using bone landmarks identified by CTA. The correct position of the catheter is signaled by pulsatile return of blood from the endoleak sac. Injection of contrast visualizes the structure of the endoleak, including the lumbar and the inferior mesenteric artery. Correct needle placement into the endoleak sac is a crucial step. Accidental puncture may damage the endograft and, theoretically, cause a new type III endoleak. Fluoroscopic guidance permitted real-time embolization in four patients of our series. Similar applications have been reported elsewhere [6, 7, 15]. After the embolization procedure, CTA and CEUS were used to confirm complete obliteration of the endoleak by correct distribution of the sealant. Pressure measurement of the aneurysm sac is a useful tool to assess the pressure in the aneurysm sac. This feature is desirable and we will implement this in the near future.

4.1. Limitations

The major limitation of our study is its retrospective design and small patient population. However, damage to the stentgraft itself by positioning the needle into the endoleak sac and thus creating a new type III endoleak did not occur in any of our patients and appears to be an unlikely event. A further limitation is that the embolization material was placed directly in the endoleak sac and not in potential efferent vessels. Once the endoleak sac has been excluded with Onyx[®], new endoleaks may be difficult to identify because they are visualized as a white entity on control X-rays. In concurrence with other authors [6, 7], we believe this issue is of no consequence as regards the long-term outcome of the procedure. The initial results obtained in our patients are encouraging. However, further studies will be necessary to verify our suggestions.

5. Conclusions

The present study demonstrates the feasibility and efficacy of translumbar access to type II endoleaks. Contrast-enhanced ultrasound is a highly sensitive method for the diagnosis and surveillance of type II endoleaks.

References

- [1] Holzenbein TJ, Kretschmer G, Thurnher S, Schoder M, Aslim E, Lammer J, Polterauer P. Mid-term durability of abdominal aortic aneurysm endograft repair: a word of caution. *J Vasc Surg* 2001;33:546–54.
- [2] Alric P, Hinchliffe RJ, Wenham PW, Whitaker SC, Chuter TA, Hopkinson BR. Lessons learned from the long-term follow-up of a first-generation aortic stent graft. *J Vasc Surg* 2003;37:367–373.
- [3] Chuter TA, Faruqi RM, Sawhney R, Reilly LM, Kerlan RB, Canto CJ, Lukaszewicz GC, Laberge JM, Wilson MW, Gordon RL, Wall SD, Rapp J, Messina LM. Endoleak after endovascular repair of abdominal aortic aneurysm. *J Vasc Surg* 2001;34:98–105.
- [4] Rhee SJ, Ohki T, Veith FJ, Kurvers H. Current status of management of type II endoleaks after endovascular repair of abdominal aortic aneurysms. *Ann Vasc Surg* 2003;17:335–344.
- [5] Maldonado TS, Gagne PJ. Controversies in the management of type II 'branch' endoleaks following endovascular abdominal aortic aneurysm repair. *Vasc Endovascular Surg* 2003;37:1–12.
- [6] Baum RA, Cope C, Fairman RM, Carpenter JP. Translumbar embolization of type 2 endoleaks after endovascular repair of abdominal aortic aneurysms. *J Vasc Interv Radiol* 2001;12:111–6.
- [7] Binkert CA, Alencar H, Singh J, Baum RA. Translumbar type II endoleak repair using angiographic CT. *J Vasc Interv Radiol* 2006;17:1349–1353.
- [8] Veith FJ, Baum RA, Ohki T, Amor M, Adiseshiah M, Blankenstein JD, Buth J, Chuter TA, Fairman RM, Gilling-Smith G, Harris PL, Hodgson KJ, Hopkinson BR, Ivancev K, Katzen BT, Lawrence-Brown M, Meier GH, Malina M, Makaroun MS, Parodi JC, Richter GM, Rubin GD, Stelter WJ, White GH, White RA, Wisselink W, Zarins CK. Nature and significance of endoleaks and endotension: summary of opinions expressed at an international conference. *J Vasc Surg* 2002;35:1029–1035.
- [9] van Marrewijk CJ, Fransen G, Laheij RJ, Harris PL, Buth J, EuroSTAR Collaborators. Is a type II endoleak after EVAR a harbinger of risk? Causes and outcome of open conversion and aneurysm rupture during follow-up. *Eur J Vasc Endovasc Surg* 2004;27:128–137.
- [10] Jones JE, Atkins MD, Brewster DC, Chung TK, Kwolek CJ, LaMuraglia GM, Hodgman TM, Cambria RP. Persistent type 2 endoleak after endovascular repair of abdominal aortic aneurysm is associated with adverse late outcomes. *J Vasc Surg* 2007;46:1–8.
- [11] Raman KG, Missig-Carroll N, Richardson T, Muluk SC, Makaroun MS. Color-flow duplex ultrasound scan versus computed tomographic scan in the surveillance of endovascular aneurysm repair. *J Vasc Surg* 2003;38:645–651.
- [12] Stavropoulos SW, Clark TW, Carpenter JP, Fairman RM, Litt H, Velazquez OC, Insko E, Farner M, Baum RA. Use of CT angiography to classify endoleaks after endovascular repair of abdominal aortic aneurysms. *J Vasc Interv Radiol* 2005;16:663–667.
- [13] Giannoni MF, Fanelli F, Citone M, Cristina Acconcia M, Speciale F, Gossetti B. Contrast ultrasound imaging: the best method to detect type II endoleak during endovascular aneurysm repair follow-up. *Interact Cardiovasc Thorac Surg* 2007;6:359–362.
- [14] Yakes WF, Rossi P, Odink H. How I do it. Arteriovenous malformation management. *Cardiovasc Intervent Radiol* 1996;19:65–71.
- [15] Schmid R, Gürke L, Aschwanden M, Stierli P, Jacob AL. CT-guided percutaneous embolization of a lumbar artery maintaining a type II endoleak. *J Endovasc Ther* 2002;9:198–202.

Translumbal treatment of type II endoleaks after endovascular repair of abdominal aortic aneurysm

Michael Gorlitzer, Gerard Mertikian, Hubert Trnka, Alexander Froeschl, Johann Meinhart, Gabriel Weiss, Martin Grabenwoeger and Thomas Rand
Interact CardioVasc Thorac Surg 2008;7:781-784; originally published online Jul 2, 2008;

DOI: 10.1510/icvts.2008.178624

This information is current as of July 27, 2009

Updated Information & Services	including high-resolution figures, can be found at: http://icvts.ctsnetjournals.org/cgi/content/full/7/5/781
References	This article cites 15 articles, 2 of which you can access for free at: http://icvts.ctsnetjournals.org/cgi/content/full/7/5/781#BIBL
Permissions & Licensing	Requests to reproducing this article in parts (figures, tables) or in its entirety should be submitted to: icvts@ejcts.ch
Reprints	For information about ordering reprints, please email: icvts@ejcts.ch

Interactive CardioVascular and Thoracic Surgery